

ACNS Standardized EEG Terminology and Categorization for the Description of  
Continuous EEG Monitoring in Neonates

Report of the American Clinical Neurophysiology Society  
Critical Care Monitoring Committee

Tammy N. Tsuchida\*, Courtney J. Wusthoff\*, Renée A. Shellhaas, Nicholas S. Abend,  
Cecil D. Hahn, Joseph E. Sullivan, Sylvie Nguyen, Steven Weinstein, Mark S. Scher,  
James J. Riviello, Robert R. Clancy

Tammy N. Tsuchida, MD, PhD  
Assistant Clinical Professor of Neurology and Pediatrics  
Children's National Medical Center  
George Washington University School of Medicine

Courtney J. Wusthoff, MD  
Assistant Professor of Child Neurology  
Stanford University School of Medicine  
Lucile Packard Children's Hospital

Renée A. Shellhaas, MD, MS  
Clinical Assistant Professor  
Pediatrics & Communicable Diseases  
University of Michigan, Ann Arbor, MI

Nicholas S. Abend, MD  
Assistant Professor of Neurology and Pediatrics  
Division of Neurology, The Children's Hospital of Philadelphia  
Departments of Neurology and Pediatrics, The University of Pennsylvania School of  
Medicine

Cecil D. Hahn, MD, MPH  
Division of Neurology, The Hospital for Sick Children  
Assistant Professor of Paediatrics (Neurology), University of Toronto  
Associate Scientist, The Hospital for Sick Children Research Institute

Joseph E. Sullivan, MD  
Assistant Professor of Neurology & Pediatrics  
Director, UC San Francisco Pediatric Epilepsy Center  
University of California San Francisco

Sylvie Nguyen The Tich, MD, PhD  
Professor of Pediatrics  
Child Neurology Unit  
Laboratoire Ingenierie Systeme Automatisees EA4094, LUNAM University Hospital  
ANGERS

Steven Weinstein, MD  
Professor of Neurology and Pediatrics Children's National Medical Center  
George Washington University School of Medicine

Mark S. Scher, MD  
Professor of Pediatrics and Neurology  
Department of Pediatrics  
Division Chief, Pediatric Neurology  
Director, Rainbow Neurological Center, Neurological Institute of University Hospitals  
Director, Pediatric Neurointensive Care Program/Fetal Neurology Program Rainbow  
Babies and Children's Hospital University Hospitals Case Medical Center

James J. Riviello, MD  
NYU Comprehensive Epilepsy Center  
NYU Langone Medical Center  
Director, Division of Pediatric Neurology  
Professor of Neurology  
Department of Neurology  
New York University School of Medicine

Robert R. Clancy, MD  
Professor of Neurology and Pediatrics  
The University of Pennsylvania School of Medicine  
The Children's Hospital of Philadelphia

\*These authors contributed equally to this manuscript.

**Background:**

Critically ill neonates are at high risk for adverse neurologic sequelae but the bedside evaluation of a neonate's neurologic status, especially cortical functioning, is extremely limited. In such circumstances, continuous video EEG provides particularly useful information about brain function and can identify electroencephalographic seizures without clinical correlate.<sup>1,2</sup> For these reasons, continuous video EEG monitoring is a useful tool in the intensive care nursery (ICN). The American Clinical Neurophysiology Society (ACNS) has recently produced guidelines regarding methods and indications for continuous EEG monitoring in neonates.<sup>3</sup>

A challenge in EEG monitoring of neonates is to understand the clinical significance of various EEG patterns. In the adult ICU population, there has been extensive debate, for example, regarding the importance of fluctuating rhythmic patterns.<sup>4-7</sup> The ACNS Critical Care Monitoring Committee has generated standardized terminology of rhythmic EEG patterns in the critically ill in order to facilitate multicenter collaborations to determine whether these patterns have clinical significance.<sup>8</sup> Neonates have distinctive EEG patterns that necessitate separate terminology.

This document is the consensus of experts to establish standardized neonatal EEG nomenclature aimed at improving consistency and facilitating collaborative research. Where evidence exists to support a particular definition, it is noted. For terms with historically variable definitions, alternative nomenclature is referenced but a single definition is proposed. We anticipate that future revisions will incorporate feedback and emerging research building upon this initial effort. Many of the studies upon which these criteria are based utilized routine-length EEG recordings and in this limited context, values such as acceptable duration of interburst intervals have been offered. However, greater variability may be expected in recordings of longer duration. Our hope is that this document provides groundwork for collaboration to determine the clinical significance of various EEG patterns in continuous monitoring of the critically ill neonate.

**DETAILS TO BE REPORTED**

Characterization of a 24 hour period of continuous video EEG recording should include:  
(Box 1)

1. Documentation of patient's postmenstrual age (PMA= gestational age, measured from the time of the last menstrual period + chronological age) at the time of recording.<sup>9a</sup>
  - a) Term = 37 up to 44 weeks PMA
  - b) Preterm = less than 37 weeks PMA
  - c) Post term = 44 to 48 weeks PMA
2. Documentation of neuroactive medications at the time of recording. This includes sedatives, hypnotics, anxiolytics, general anesthesia, and anti-epileptic drugs. An

---

<sup>a</sup> We use the term PMA here in accordance with the American Academy of Pediatrics policy statement on age terminology in the perinatal period. However, we recognize that historically, many seminal investigations of EEG ontogeny calculated gestational age from the time of conception rather than the last menstrual period. This has been traditionally termed conceptional age (CA). The LMP occurs about 2 weeks before conception.

ideal report would also document when these medications are administered during the recording.

3. Documentation of the depth and duration of hypothermia during the recording, and whether it is spontaneous or induced.
4. An ideal report would also document clinical changes that have the potential to impact cerebral function. These would include sudden hemodynamic instability, rapid changes in respiratory function or cardiorespiratory failure.
5. Documentation of the number of hours of recording that cannot be interpreted due to technical problems.
6. Detailed characterization of the background EEG features during the first hour of recording. Presence or absence of state changes must be included.
7. Characterization of one hour of background recording within each 24 hour period of EEG monitoring.
8. Characterization of additional epochs of background when there are relevant changes. Relevant changes include not only evidence for increasing encephalopathy but also the new development of episodic state changes.
9. Documentation of seizure onset, seizure burden, and seizure resolution. When present, specific note should also be made of the beginning and end of status epilepticus.

The normal neonatal EEG evolves as the brain matures, reflecting both antenatal and postnatal experiences. All else being equal, two healthy infants with the same PMA should have very similar appearing EEG recordings. There should be no visible differences between an EEG recorded from a 5 weeks chronological age infant born at 35 weeks EGA (PMA = 40 weeks) compared to a 1 week chronological age baby born at 39 weeks EGA (PMA is also 40 weeks). However, in contrast to the older child or adult, a few weeks' age difference can cause visible changes in normal EEG features. The following text proposes nomenclature to describe normal and abnormal features of the EEG in the preterm and term infant. Where relevant, it refers to the specific PMA at which various features are seen. We focus specifically on normal state changes, background features, graphoelements (or named neonatal EEG features), seizures, and rhythmic or periodic patterns.

## **BEHAVIORAL STATE**

Standardized descriptions of the behavioral state and sleep-wake cycling are particularly useful in considering whether a neonatal record is normal or abnormal. Features of a full term neonatal EEG and polysomnographic recording emerge over time in the premature infant. A behavioral state is said to be present when features of that state are present for one minute or longer (Box 2)

### **Awake**

**Term.** A healthy term neonate is awake when the eyes are open and the EEG background has continuous, low to medium voltage (25-50  $\mu$ V peak-to-peak (pp))<sup>b</sup> mixed frequency

---

<sup>b</sup> All voltages included in this manuscript refer to peak-to-peak (pp) values.

activity with a predominance of theta and delta and overriding beta activity.(Figure 1) This is traditionally called *activité moyenne*, roughly meaning “average or medium” EEG background activity. During wakefulness, term infants have irregular respirations and there are spontaneous movements of the limbs and body.

**Preterm.** A healthy preterm infant is considered awake when the eyes are open. This remains its premier clinical characteristic until 32-34 weeks PMA, when other polysomnographic signs (irregular respiratory patterns, phasic or tonic chin EMG activity, and the presence of small and large body movements) are also reliably concordant with wakefulness. Brief portions of the awake EEG are continuous at 28 weeks PMA. The awake background is even more continuous by 32 weeks and persistently continuous by 34 weeks and thereafter.

## Sleep

Sleep in the neonate is classified as active, quiet, transitional, and indeterminate. Each has distinctive EEG and polysomnographic features.

### Active Sleep

**Term.** The healthy term neonate in active sleep has the eyes closed, intermittent periods of rapid eye movements (REM), and irregular respirations with small and large body movements. The EEG background shows *activité moyenne*, indistinguishable from that of normal wakefulness.

**Preterm.** *Tracé discontinu* describes the normal discontinuous tracing encountered in healthy preterm babies (Figures 1, 2a). This EEG pattern is characterized by bursts of high voltage (50-300  $\mu$ V pp) activity that are regularly interrupted by low voltage interburst periods (< 25  $\mu$ V pp).<sup>10</sup> The duration of the low voltage interburst periods is dependent on PMA, being longest in the youngest PMA infants. The bursts of EEG activity have expected and recognizable constituents such as monorhythmic occipital delta activity and other patterns that are described below. *Tracé discontinu* predominates before 28 weeks PMA. Brief and inconsistent periods of continuous EEG activity occur first in waking state and active sleep along with rapid eye movements (REM) at 25 weeks PMA.<sup>11</sup> Movements (face and body) in active sleep tend to be segmental myoclonus or generalized myoclonic and tonic posturing. By 28-31 weeks PMA, there are some periods with complete features of active sleep (eyes closed, REM, irregular respirations, body movements and continuous EEG). After 34 weeks active sleep consistently has continuous EEG activity.

### Quiet Sleep

**Term.** In the healthy term neonate, quiet sleep is clinically characterized by eye closure, absent REM, and scant body movements, except for occasional sucking activity or generalized myoclonic “startles”. The quiet sleep EEG background near term, *tracé alternant*, evolves from the less mature *tracé discontinu* in the preterm (Figures 1, 2b). It shows the “alternating tracing” in which higher voltage bursts (50-150  $\mu$ V pp), comprised predominantly of delta activity and lasting roughly 4 to 10 seconds, *alternate* with

brief, lower voltage (25-50  $\mu\text{V}$  pp)<sup>12</sup> interburst periods composed mostly of mixed theta and delta activity. These interburst periods of tracé alternant, taken in isolation, greatly resemble the characteristics of activité moyenne with its low to medium voltage, mixed frequency activity. Tracé alternant gradually disappears with age and is minimal by 42 weeks and vanishes by 46 weeks. As tracé alternant fades, it is replaced in quiet sleep by the more mature, fully continuous quiet sleep background comprised of non-stop, high voltage (50-150  $\mu\text{V}$  pp) delta and theta activity. Sleep spindles around 10-12 Hz first appear within this continuous slow wave sleep pattern by 46 weeks PMA.

**Preterm.** In the very preterm neonate, most of the EEG background is discontinuous in all behavioral states. With advancing PMA, wakefulness and active sleep are distinguished from quiet sleep by greater periods of continuity. Tracé discontinu is the defining feature of quiet sleep first emerging around 28 weeks PMA. By 34-36 weeks tracé discontinu is seen only in quiet sleep. The amount of time with a tracé discontinu pattern decreases with increasing PMA so that a term infant has rare, if any, periods of tracé discontinu in quiet sleep.<sup>13</sup> By 37-40 weeks, tracé alternant fully replaces tracé discontinu as described above.

### **Transitional Sleep**

In between states of waking, active sleep and quiet sleep, there are temporary *transitional* periods in which typical features for a specific behavioral state are incomplete. These transitional sleep states typically blend together clinical and EEG features of the original and final behavioral states. Transitional sleep does not clearly satisfy the polysomnographic and EEG background criteria for a specific state as defined above. For example, in the transition from active sleep to quiet sleep, an infant might still show some large body movement but deep regular respirations accompanied by an EEG that is between activité moyenne and tracé alternant. This admixture of the two states is seen until quiet sleep fully emerges and satisfies all the criteria for definite quiet sleep. Transitional sleep can be thought of as a temporary period of indeterminate sleep, as described below.

### **Indeterminate Sleep**

Segments of the EEG in which the baby's eyes are closed (indicating sleep) but in which other clinical and EEG features do not permit definite assignment to active or quiet sleep are designated as indeterminate sleep. These periods lack the anticipated features for assignment to a unique sleep state. As above, transitional sleep is a temporary kind of indeterminate sleep. Much of sleep is indeterminate in very preterm infants in whom there is not a well established concordance between the EEG background and polysomnographic variables. Only a small amount of total sleep time is indeterminate in healthy term infants. A high percentage of total sleep time that is indeterminate would be considered abnormal at term.

### **Sleep-wake cycling**

Sleep-wake cycling is the pattern of alterations among behavioral states. Cycling is more distinctive and easier to recognize in term babies, compared to preterm babies. It is also easier to detect in long term recordings than brief routine tracings.<sup>11</sup>

**Term.** In the term infant, a complete sleep and waking cycle typically has a duration of 3-4 hours.<sup>14</sup> An isolated sleep-only cycle typically lasts 40-70 minutes and progresses in a somewhat orderly fashion. The awake term infant usually first falls into an active sleep state. This is true until about four months after term equivalent age. Tracé alternant may then appear in the first portion of quiet sleep and gradually be replaced by continuous high voltage slow activity. Term neonates spend approximately 50-60% of the sleep cycle in active sleep, 30-40% in quiet sleep and 10-15% in transitional sleep.

**Preterm.** The proportion of time spent in any state also varies by age.<sup>11, 15</sup> The first rudimentary evidence of sleep cycling can be seen at 25 weeks PMA. At 27-34 weeks PMA, 40-45% is spent in active sleep, 25-30% in quiet sleep, and 30% in indeterminate sleep. Beyond 35 weeks PMA, infants spend 55-65% of the time in active sleep, 20% in quiet sleep and 10-15% in indeterminate sleep. The duration of a sleep cycle (first active sleep, then transitional sleep and finally quiet sleep) is 30-50 minutes for neonates <35 week PMA and increases to 50-65 minutes beyond 35 weeks PMA.

**Unspecified State Changes.** In a sick infant with disruption of normal background features, it may be difficult or impossible to identify definite specific sleep states. However, some infants can still have state changes, defined as cycling between distinctly different EEG patterns as indicated by the amount of background discontinuity, voltages or electrical frequencies with at least one minute in each unspecified state.

## **EEG BACKGROUND**

The constituents of normal neonatal EEG background evolve with PMA. In the following section, the features of both normal and abnormal EEG backgrounds will be defined. (Box 3)

### **Continuity**

#### **Normal Continuity**

EEG activity is continuous when there is uninterrupted, non-stop electrical activity with less than 2 seconds of voltage attenuation <25  $\mu$ V pp. The entire evolution of the normal EEG background proceeds from the persistently discontinuous tracing in all behavioral states in extremely premature infants to continuous EEG in all states in fully mature infants.

#### **Discontinuity**

Discontinuous EEG activity is broadly recognized as higher voltage “bursts” of electrical activity interrupted by lower voltage “interbursts”. The intervening periods of attenuation are termed interburst intervals (IBI). The durations in seconds of the IBIs are a function

of age, being longest in very preterm infants and shortest during tracé alternant quiet sleep at term. We define the IBI as a period in which activity is attenuated  $<25\text{-}50\ \mu\text{V pp}$  for two seconds or more. The literature has historically proposed various definitions for classifying EEG patterns on the basis of IBI. The definitions offered here are attempted compromises from these.<sup>12, 13</sup> (Table 1) The background can still be called discontinuous if there is modest activity within the IBI in a single electrode or a single transient in multiple electrodes.

**Normal Discontinuity.** There is a progressive decrease in normal IBI durations with increasing PMA.<sup>12, 13</sup> Tracé discontinu, as defined above, is a normal discontinuous EEG pattern in preterm infants (Figures 1, 2a). The electrical activity within the bursts includes age-appropriate graphoelements such as rhythmic occipital delta activity and other specific, named patterns that are described below. It is present in varying amounts from 26-40 weeks PMA. It appears first in wakefulness, active and quiet sleep (until 30 weeks PMA), then only in quiet sleep, and is rarely seen in infants 38 weeks PMA or older.<sup>13</sup>

Tracé alternant, as already defined, depicts a point of transition from complete discontinuity to full continuity. It is only seen in quiet sleep. In the transition from tracé discontinu to tracé alternant, the durations of the IBIs shorten while their voltages swell until all the gaps of immature discontinuity have been filled in. While bursts of 50-150  $\mu\text{V}$  delta activity alternate with lower voltage theta activity of 25-50  $\mu\text{V}$ , these lower voltage periods never completely attenuate. In contrast to tracé discontinu, the voltages are never less than 25  $\mu\text{V pp}$ .<sup>12</sup> (Figures 1, 2b) Like tracé discontinu, the abundance of this pattern varies by age. Tracé alternant is first seen at 34-36 weeks PMA, becomes minimal by 42 weeks and is no longer seen by 46 weeks PMA.

#### **Excessive Background Discontinuity**

In sick newborn infants who have experienced a variety of causes of encephalopathy (such as HIE, intracerebral bleeding, sepsis-meningitis, etc.), the two main reported categories of background abnormalities are pathologically excessive discontinuity and abnormally low voltage for PMA.<sup>16</sup> We suggest restricting the term “excessive discontinuity” to abnormally discontinuous tracings with bursts that contain some normal patterns and graphoelements separated by IBIs that are too prolonged or voltage depressed for PMA, as defined by the parameters in Table 1 (Figures 1, 2c).<sup>10</sup> This is an area that can be addressed and better quantified by future study using standardized methodology to correlate IBI with patient outcomes.

#### **Burst Suppression**

Further disruption of EEG continuity results in the more severe burst suppression pattern. This consists of invariant, abnormally composed EEG bursts separated by prolonged and abnormally low voltage IBI periods, strictly defined as IBI voltages  $<5\ \mu\text{V pp}$  (Figures 1, 2d). However the definition does allow for one electrode with sparse activity during the IBI up to 15  $\mu\text{V pp}$ , or less than two seconds with transient activity up to 15  $\mu\text{V pp}$ , or  $> 2:1$  asymmetry in voltage in multiple electrodes.



In all cases, the EEG should be invariant, with no spontaneous discontinuity changes due to internally mediated lability and no EEG change of reactivity due to external noxious stimulation of the infant. The presence of high ( $> 100 \mu\text{V pp}$ ) or low ( $<100 \mu\text{V pp}$ ) voltage activity in the bursts should be described. The composition of the bursts of the EEG activity is characterized by non-specific theta, delta, beta and admixed sharp waves but is devoid of specific graphoelements such as monorhythmic occipital delta activity, delta brushes or other recognizable graphoelements. This is a key feature distinguishing burst suppression from excess discontinuity: *burst suppression has no normal features within the bursts, while excessively discontinuous records have some normal patterns identifiable within the bursts*. Similarly, burst suppression is an invariant pattern, while excess discontinuity contains some variability or reactivity.

If burst suppression occurs, typical burst and IBI duration should be recorded. Further characterization should include a description of the “sharpness” of the components of a typical burst (see below “Rhythmic and Periodic Patterns of Uncertain Significance”- Modifier “Sharpness”). In some individuals, the bursts are composed entirely of non-specific frequencies but in others, unequivocal sharp waves appear admixed within the bursts.

### **Symmetry**

**Normal Symmetry.** In the normal neonatal EEG, electrical voltages, frequencies, and the distribution of specific, named graphoelements should be reasonably equally represented between homologous regions of the two hemispheres. The left and right hemispheres should be more or less electrographic mirror images of each other. This allows for fleeting, transient asymmetries to occasionally occur, while still considering the record symmetric overall.

**Abnormal Asymmetry.** The persistence of more than a 2:1 difference in voltages between homologous regions of the two hemispheres, or a clear disparity of background features, including the fundamental electrical frequencies and the distribution of specific graphoelements between the two sides is abnormal. Since focal lesions (arterial ischemic stroke, sinovenous thrombosis, localized bleeding, abscess, etc) account for up to 10% of acute neonatal encephalopathies, EEG background asymmetries are not rare and may be diagnostically relevant.

### **Synchrony**

Synchrony is defined as the onset of bursts of activity that occur nearly simultaneously between hemispheres in the discontinuous portions of the recording. For example, a single burst within tracé discontinu would be considered synchronous if the onsets of the left and right hemisphere bursts occur within 1.5 seconds of each other. The reader assesses the percentage of bursts that are synchronous within the discontinuous portions of the study.

**Normal synchrony.** The percentage of synchronized bursts is not a linear function of PMA. Prior to 27-29 weeks PMA, EEG activity is almost completely synchronous.<sup>17, 18</sup> Between 29 and 30 weeks PMA, EEG activity may only be about 70% synchronous. From approximately 30 to 37 weeks PMA, more synchronous activity emerges until term when the EEG is nearly 100% synchronous again.

**Normal Asynchrony.** As above, some degree of asynchrony is expected and normal between 30 and 37 weeks PMA. By 38 weeks PMA the EEG should not show any substantial amount of asynchrony.

**Abnormal Asynchrony.** This is defined as a clearly excessive percentage of EEG bursts for PMA that occur asynchronously (greater than 1.5 seconds between onset of activity in each hemisphere) during the discontinuous portions of the recording.

## Voltage

Few studies have defined the normal boundaries for voltage (or amplitude) in premature infants. Thus, there will be no attempt to offer normal voltage criteria for abnormality in this group. The focus of this section will therefore be the boundaries of normal voltage for the term infant. (Figure 1) Just as with the older child or adult, *voltage abnormalities should be interpreted with caution* as many extracerebral conditions (such as poor electrode impedance or inaccurate electrode placement, scalp edema, cephalohematoma, and subdural hemorrhages) can artificially result in low voltage EEG activity or interhemispheric voltage asymmetries. Strict voltage thresholds are therefore difficult to determine.

### Normal Voltage

A healthy term infant should have most EEG activity  $\geq 25 \mu\text{V}$  pp in all behavioral states.

### Borderline Low Voltage

This is defined as a continuous EEG background containing some normal activity and graphoelements with representative voltages persistently at least  $10 \mu\text{V}$  but less than  $25 \mu\text{V}$ . The clinical significance of borderline low voltage is not certain.

### Abnormally Low Voltage

#### Low Voltage Suppressed

There are various definitions in the literature of an abnormal background due to a low voltage or “low voltage undifferentiated” pattern.<sup>19-21</sup> We propose a definition of *persistently low voltage activity without normal background features*. The fundamental baseline voltage is less than  $10 \mu\text{V}$  pp. The background can be interspersed with higher voltage ( $\geq 10 \mu\text{V}$  pp) transient activity for less than two seconds. In addition, the record is *invariant*, with no inherent lability, and *unreactive*, with no EEG changes from external stimulation. This pattern suggests severe neurologic injury with diffuse death or dysfunction of the cortical neuronal generators of EEG activity.

**Comment [TT1]:** <15uV invariant?  
Based on Holmes 1982, monod  
1972. Monod say +/- reactive

### **Electrocerebral inactivity (ECI)**

This terminology is used to describe the absence of discernible cerebral electrical activity  $\geq 2 \mu\text{V}$  pp when reviewed at a sensitivity of  $2 \mu\text{V}/\text{mm}$ .<sup>22</sup> The term ECI has largely replaced the previous terms “electrocerebral silence” (ECS) and isoelectric recordings, although their implications are the same. Published guidelines detail the technical requirements needed for performing an EEG to assess for ECI.<sup>23</sup> These are distinct from the technical requirements for standard neonatal EEG recordings. If the EEG is not performed according to these standards, the term ECI should not be applied. If there is no discernible cerebral activity, but the recording was not conducted according to the ECI guidelines, the report should indicate that the recording *may be consistent with ECI*, but should specify ECI cannot be determined without the appropriate technical parameters. ECI is a pattern which, when coupled with appropriate clinical examination and/or neuroimaging, is used to determine cerebral death.<sup>22, 24-27</sup> Clinicians are advised to consult their institutions’ guidelines regarding the determination of brain death for newborn infants, as practices vary.

### **Variability**

Variability (lability) denotes conspicuous spontaneous EEG responses to internal stimuli such as occur during typical sleep-wake cycling. It is first present by 25 weeks when the EEG initially demonstrates nascent changes with biobehavioral state. Variability should be increasingly apparent by 28 weeks PMA and well established by 30-31 weeks PMA. The EEG responses can consist of changes in *any* electrical domain: frequency, continuity, or voltage. It is important to note that arousals from sleep can result in transient attenuation of EEG voltages which should not be mistaken for discontinuity. Variability should be recorded as Yes, No, or Unclear/unknown/not applicable. For example, variability would obviously be present in a 60 minute recording which captured multiple behavioral states such as wakefulness, transitional, active and quiet sleep. The last choice might apply, for example, in a 60 minute recording that captured only an awake state

### **Reactivity**

EEG reactivity is demonstrated when there is a conspicuous cerebral EEG response to external stimulation. Like lability, these EEG responses also consist of changes in any electrical domain: frequency, continuity, or voltage. The clinical and behavioral components of reactivity can include crying, movement, EMG activity, and respiratory pattern changes. It is important to note that after internal or external stimulation, behavioral responses may induce artifacts from movement or EMG activity that may mimic actual changes of the EEG background. Reactivity first appears at 30-32 weeks PMA, but might not be seen with each and every external stimulation. Reactivity should be recorded as Yes, No, or Unclear/unknown/not applicable. Strength and/or nature of stimulus should be noted.

### **Dysmaturity**

The traditional scenario in which the term *dysmaturity* was coined involved very premature infants with chronic illnesses such as bronchopulmonary dysplasia. Over time, their EEG background features sometimes failed to mature at the same rate as their PMA progressed. There was eventually a gap between their actual PMA and their maturity as suggested by the appearance of their EEG backgrounds. This disparity in maturity between the actual PMA and their “EEG PMA” is termed dysmaturity, defined as an EEG that would be normal for an infant at least two weeks younger than the stated PMA. The persistently dysmature EEG is considered abnormal and is associated with an increased risk of abnormal neurologic outcome.<sup>22, 28</sup>

### **NORMAL GRAPHOELEMENTS (DEVELOPMENTAL BACKGROUND HALLMARKS)**

In neonatal EEG, graphoelements are normal, expected, specific, named EEG background patterns that first appear, peak and then fade during particular epochs of neonatal development. They are characteristic of specific PMAs. They are part of the composition of the normal EEG background and are thus typically symmetric. Not every known type of specific graphoelement is included below; we have defined the most commonly seen. (Box 4)

**Monorhythmic Delta Activity.** This pattern occurs between 24 and 34 weeks PMA and consists of moderately high voltage (up to 200 $\mu$ V pp) delta activity with a relatively stereotyped morphology. It may be predominantly occipital, temporal and/or central, but is rarely frontal.<sup>18</sup> Is typically synchronous and symmetric, and often surface positive.

**Delta Brushes.** Delta brushes have been described under many names, including beta-delta complexes, spindle-delta bursts, spindle-like fast waves, or ripples of prematurity. These are most prominent between 24 and 36 weeks PMA and consist of a combination of 0.3-1.5 Hz slow waves of 50-250  $\mu$ V pp with superimposed fast activity (8-12 or 18-22 Hz).<sup>12</sup> Their peak expression is between 32 and 34 weeks PMA. They are maximal in active sleep up to 32 weeks and after that are seen in wakefulness and quiet sleep then are maximal in quiet sleep between 33 and 37 weeks PMA.<sup>17, 18</sup> They are occasionally seen in quiet sleep up to 40 weeks PMA.

**Rhythmic Temporal Theta.** This graphoelement occurs between 24 and 34 weeks PMA. It typically consists of 25-120  $\mu$ V pp theta frequency activity for short (two second) bursts over the temporal region. It is typically symmetric, and maximal between 29 and 32 weeks PMA.<sup>12, 17, 18</sup> Morphologically similar activity can be seen at the vertex and occipital regions.

**Anterior Dysrhythmia.** Despite its somewhat misleading name, this is a normal graphoelement. It first appears at 32 weeks and persists until 44 weeks PMA. It consists of 50-100  $\mu$ V pp delta waves which may occur in isolation or brief runs for a few seconds over the frontal regions.<sup>12, 18</sup> It is typically synchronous and symmetric.

**Encoches Frontales.** This pattern is intimately related to anterior dysrhythmia and the two are often seen admixed over the frontal regions. (Figure 3a) Encoches frontales occur between 34 and 44 weeks PMA and consist of 50-100  $\mu$ V pp broad diphasic transients (0.5-0.75 sec) with a small initial negative deflection and a larger positive deflection.<sup>10, 12, 18</sup> Overall, they are typically synchronous and symmetric. They are often present in transitional sleep and most abundant in the transition from active to quiet sleep.<sup>17, 18</sup>

## EEG TRANSIENT PATTERNS

As opposed to the fundamental EEG background, which is the basic ongoing cerebral electrical activity, there are also transient EEG patterns that may intermittently punctuate the background. (Box 5)

### **Sharp Wave Transients**

Many healthy neonates have normal, physiologic sharp wave transients while some sick newborns show abnormal or excessive sharp wave transients that imply pathology. There remains debate regarding the boundaries that separate physiologic from pathologic sharp wave transients. Sharp wave transients are characterized by their negative or positive polarity, duration, abundance, spatial distribution, and repetitive behavior.

A negative sharp wave transient has an initial and predominant deflection that is surface negative. A positive sharp wave transient has an initial and predominant deflection that is surface positive. Both need to be clearly distinct from the background as separate transients and not just “sharply contoured background activity”. Sharp wave transients lasting < 100 msec are commonly called *spikes*. Sharp wave transients lasting 100-200 msec are commonly called *sharp waves*. It is notable that the typical neonatal display of 15mm/seconds time compresses the appearance of the background, and many EEG features will appear more sharply contoured than if the recording were viewed at the typical adult or pediatric display setting of 30mm/sec.

Quantification of the abundance of sharp wave transients (the number of spike or sharp waves per minute at a given location such as the central or temporal regions) should be undertaken in the most continuous portions of the neonatal EEG: wakefulness or active sleep. In the discontinuous portions of the record, particularly during tracé alternant, the EEG bursts often have fleeting sharply contoured activity embedded within the background, rather than truly distinct EEG transients separate from the background. Sharp wave transients can appear at any electrode location. Sharp wave transients may occur as single, solitary events or recur in brief repetitive runs or trains.

### **Physiologic Negative Sharp Waves.**

Physiologic negative sharp waves lasting 100-200 msec are commonly seen in the EEGs of healthy near-term and term infants (Figure 3b). They are typically observed against the backdrop of a normal EEG background for PMA. They appear in greatest abundance in the mid-temporal, central and centro-temporal regions. They are rare in the frontal,

midline vertex and occipital regions. They are symmetrically distributed between homologous regions of the hemispheres. They are mostly single, solitary transients but a few may appear in brief trains or runs.<sup>28</sup>

### **Abnormal Negative Sharp Wave Transients**

These appear as sharp waves or true spikes (Figure 3c). They most commonly arise in the context of an abnormal EEG background for PMA. Although they may also appear in the familiar mid-temporal, central or centro-temporal locations, they may be heavily concentrated in one region or hemisphere, rather than being randomly or evenly distributed spatially. They may also be seen in atypical locations such as the frontal, midline vertex or occipital regions. They may be much more abundant compared to physiologic negative sharp wave transients. Data for neonates who were assessed developmentally at  $\geq$  one year old indicate that negative sharp waves more frequent than 11 per hour for preterm and 13 per hour for term infants are abnormal.<sup>29-34</sup> Abnormal negative sharp EEG transients are more likely than physiologic negative sharp waves to recur in brief runs or trains.<sup>35</sup>

### **Positive Sharp Wave Transients.**

Historically, these were first described in the EEGs of preterm infants who developed significant intraventricular hemorrhages. Positive sharp waves were described in the Rolandic regions (positive Rolandic sharp waves or PRS), represented by electrodes C3 and C4, although it was later recognized that many were actually maximally situated at the midline vertex (positive vertex sharp waves-PVS) with field spread to the adjacent Rolandic regions.<sup>36</sup> It is now appreciated that PRS and PVS are most closely pathologically associated with underlying white matter injury including periventricular leukomalacia.<sup>37</sup>

In the term infant, excessive positive sharp waves in the mid-temporal regions can signify underlying focal pathology such as a localized hemorrhage or white matter injury. However, these are more difficult to judge since rare scattered temporal sharp waves can be occasionally seen in apparently healthy term infants. Previous work suggests up to 3 per hour for preterm and 1.5 per hour for term neonates may be normal.<sup>38,39</sup>

### **Brief Rhythmic Discharges (BRD).**

This transient EEG pattern consists of evolving rhythmic patterns of electrical activity that share many characteristics with seizures but are very brief, with a duration less than ten seconds.<sup>40-42</sup> These have previously been alternatively described in the literature as BIRDs (Brief Ictal/Interictal Rhythmic/Repetitive Discharges) and BERDs (Brief Electrographic Rhythmic Discharges). Given that the true significance of these discharges is uncertain, the operational term “BRD” will be used here. They are usually seen in the context of an abnormal EEG background and/or confirmed electrographic seizures. BRDs are rarely seen in isolation in a normal EEG. At this time, their pathological significance is not fully understood. However, recent studies in adults suggest that clinical behavior changes can coexist with epileptiform discharges under two seconds in duration.<sup>43</sup> Similarly, a case series demonstrated similar mortality and

neurologic disability for infants with BRDs as with seizures.<sup>41</sup> Further study is needed to better understand the basis and significance of brief rhythmic discharges in the neonate.

## **SEIZURES AND STATUS EPILEPTICUS**

### **Neonatal Seizures**

Neonatal seizures are traditionally classified as clinical-only, electroclinical or electrographic-only seizures. A *clinical-only seizure* consists of a sudden paroxysm of abnormal clinical changes that do *not* correlate with a simultaneous EEG seizure. These clinical changes may include unnatural posturing, obligatory stereotyped movements, sudden arrested behaviors or autonomic dysfunction (episodic tachycardia or hypertension, flushing, pallor or salivation, etc.). An *electroclinical seizure* features definite clinical seizure signs simultaneously coupled with an EEG seizure.<sup>44</sup> An *EEG-only seizure* refers to the presence of a definite EEG seizure that does not provoke any specific outwardly visible clinical signs. For the purposes of this document, the term "seizure" hereafter refers to electrographic seizures, with or without coupled clinical signs of seizure.

An electrographic seizure is a sudden, abnormal EEG event defined by a repetitive and evolving pattern with a minimum  $2\mu\text{V}$  pp voltage and duration of at least ten seconds. A seizure is always an abnormal pattern and should not be confused with transient background changes, such as those associated with drowsiness or arousal from sleep. "Evolving" is defined as an unequivocal evolution in frequency, voltage, morphology or location. In contrast, brief rhythmic repetitive discharges lasting less than ten seconds but with evolution would be considered BRDs and not seizures. Likewise, rhythmic, repetitive activity lasting more than ten seconds but without evolution would be considered periodic discharges or rhythmic activity, but not a seizure (Figure 3c). While  $2\mu\text{V}$  pp defines the boundaries of the beginning and end of each seizure, the voltages predictably increase as the seizure evolves and can be up to  $150\mu\text{V}$  pp or more. Unlike seizures in older children and adults, *there is no minimum electrical frequency required* in the definition of seizure. To be classified as *separate seizures*, ten seconds or more must separate two distinct seizure events.<sup>45,46</sup>

Several aspects of a seizure can be quantified. In the older child and adult, the ACNS standardized research terminology describes the typical, minimum and maximum frequency (Hz) during a seizure.<sup>8</sup> This is of uncertain significance in the neonate. Seizure location can be described in terms of the focus (site of onset) and maximal spread, represented by the greatest number of electrodes involved. Recommended terminology to describe *seizure spread* includes:

- **Diffuse (D)** - asynchronous involvement of all electrodes by focal seizures of extensive geographic distribution. This contrasts with children and adults who can have truly generalized, synchronous and symmetric activity.
- **Bilateral independent (BI)** – a seizure with activity occurring simultaneously in two regions but which begin, evolve and behave independently of each other.
- **Migrating (Mig)** - seizure moves sequentially from one hemisphere to another

- Lateralized (L) - all of the seizure propagates within a single hemisphere (LH or RH).
- When a seizure is restricted to a confined region, it can be further described as frontal (F), central (C), temporal (T), occipital (O) or Vertex (Z) or it can be described more broadly as anterior quadrant (Ant), posterior quadrant (Post).
- When multiple seizures arise from a single general region, they can be classified as unifocal onset.
- Multifocal (Mf) onset seizures originate from at least three independent foci with at least one in each hemisphere. It is not uncommon for localized lesions such as a stroke to precipitate unifocal seizures, while diffuse insults such as meningitis may provoke multifocal onset seizures.
- .

Seizure burden has been quantified in various ways.<sup>1, 45, 47-49</sup> We propose quantifying seizure burden for clinical purposes using one of the following definitions:

- 1) Frequency: the number of seizures per hour, or
- 2) Percent of the record with seizures: the total summed duration of all the seizures divided by the entire duration of an epoch of interest, or
- 3) Temporal-spatial quantification: The most detailed metric of seizure burden that could be used for research purposes includes the total summed durations of seizures in each region of interest, per hour.<sup>50</sup> In this case, the neonatal montage could be collapsed into five non-overlapping regions of interest: Fp3-T3, C3-O1, Fp4-T4, C4-O2 and Fz-Pz (or alternatively Fp3-C3, T3-O1, Fp4-C4, T4-O2 and Fz-Pz). Thus, each single electrode is counted only once. The total summed seizure durations can be calculated separately for each of the five regions of interest, which provides a temporal-spatial metric of seizure burden. Future work is needed to determine the relative utility of these more labor intensive methods.

**Comment [TT2]:** should reference Mark's paper about interrater reliability of one temporal spatial quantification system

## Status Epilepticus

The traditional definition of status epilepticus in children and adults is a single seizure lasting more than 30 minutes or a series of seizures lasting at least 30 minutes between which baseline brain function has not been restored.<sup>42</sup> These criteria are difficult to apply to neonates, given the difficulty assessing their mental status and the high incidence of co-existing acute encephalopathy. Consequently, other definitions of neonatal status have been offered.<sup>46</sup> In consensus with the current literature, we propose a definition of status epilepticus as present when *the summed duration of seizures comprises  $\geq 50\%$  of an arbitrarily defined one hour epoch*. In other words, if half or more of any given hour of recording shows seizures, status epilepticus exists for that epoch.

In a population of neonates with recorded electrographic seizures, the percentage of recording time in which seizures are detected could range from 1% to 100%. It is recognized that our definition of status is a somewhat arbitrary and that there are no data that specifically justify the choice of 50% over any other percentage value as especially meaningful or significant. Alternative research definitions of status could be explored based on available data regarding typical durations of electrographic neonatal seizures. In



two studies in neonates, the median EEG seizure length was one minute, with 75% of seizures lasting  $\leq 2.5$  minutes.<sup>45, 48</sup> In these and another study, the range of individual seizure duration was 10 seconds–46 minutes, and the mean seizure length was 2–4 minutes.<sup>45, 46, 48</sup> In future studies it will be useful to characterize different categories of seizure burden and duration of status epilepticus as they relate to outcomes.

### **RHYTHMIC AND PERIODIC PATTERNS OF UNCERTAIN SIGNIFICANCE**

Some rhythmic patterns do not demonstrate the unequivocal evolution in frequency, morphology or location characteristic of seizures. These are targets of active investigation in the older ICU population as they are common and their clinical significance is unclear. Pathologic rhythmic and periodic patterns do occur in preterm and term neonates but are not common.<sup>51</sup> It is unclear whether research terminology that has been developed in adults is applicable to the neonate.<sup>8</sup> We discuss below the patterns from the adult terminology which have been described previously in neonatal literature.

#### **Patterns**

**Periodic.** Periodic discharges (PD) are defined in the adult terminology as a pattern in which waveforms have a relatively uniform morphology and duration, there is a quantifiable interval between consecutive waveforms and the waveforms recur at nearly regular intervals. “Discharges” are defined as waveforms with no more than three phases [i.e. crosses the baseline no more than twice] or any waveform lasting 0.5 seconds or less, regardless of number of phases). In contrast, bursts are defined as waveforms lasting more than 0.5 seconds and having at least four phases [i.e. crosses the baseline at least three times]. “Nearly regular intervals” is defined as having a cycle length (i.e., period) varying by  $<50\%$  from one cycle to the next in the majority ( $>50\%$ ) of cycle pairs.(Figure 3c). PD are not common in neonates, but can occur with acute destructive processes such as HSV encephalitis, stroke or global hypoxia ischemia.<sup>51-53</sup>

**Rhythmic.** Rhythmic delta activity (RDA) is defined in the adult terminology as the repetition of a waveform with relatively uniform morphology and duration but without an interval between consecutive waveforms. To qualify as rhythmic, the duration of one cycle (i.e., the period) of the rhythmic pattern must vary by  $<50\%$  from the duration of the subsequent cycle for the majority ( $>50\%$ ) of cycle pairs. Importantly, this EEG pattern may not be abnormal in neonates and is consistent with some normal neonatal graphoelements: rhythmic occipital delta activity and anterior dysrhythmia.

#### **Duration**

The periodic or rhythmic pattern must be present for at least six cycles (e.g. 1/second for six seconds or 3/second for two seconds).

#### **Location**

Location can be described in terms of the focus (site of onset) and maximal spread (maximal electrodes involved). Location can be Lateralized (L) or Diffuse (D). Lateralized includes unilateral focal/regional/hemispheric and bilateral asymmetric activity. In Diffuse activity (D), there is asynchronous involvement of all electrodes. The

term Diffuse can be applied to bilateral hemispheric involvement even if the activity has a restricted field (e.g. bifrontal). Patterns may also be Bilateral Independent (BI) or Multifocal (Mf).

Additional localizing information may include a description of the predominant location. For diffuse (D), one can specify frontally-predominant, occipitally-predominant, midline predominant or 'generalized, not otherwise specified'. Frontally predominant is defined as having an amplitude in anterior derivations that is at least 50% greater than that in posterior derivations on an ipsilateral ear, average, or non-cephalic referential recording. Occipitally predominant is defined as having an amplitude in posterior derivations that is at least 50% greater than that in anterior derivations on an ipsilateral ear, average, or non-cephalic referential recording. Midline predominant is defined as having an amplitude in midline derivations that is at least 50% greater than in parasagittal derivations on an average or non-cephalic referential recording. For lateralized (L), bilateral independent (BI) or multifocal (Mf) patterns, one can specify the area(s) most involved (F, C, T, O, Z or hemispheric if more specific localization is not possible) and whether the activity is bilateral asymmetric or unilateral. If activity is bilateral but asymmetric (BI or Mf), the most involved areas (F, C, T, O, Z or hemispheric) can be specified over both hemispheres.

### **Modifiers**

Rhythmic patterns can be further described using “modifier” terms according to the ACNS Standardized Critical Care EEG Terminology 2012. The modifier “evolving” does not apply to neonates since this defines a neonatal seizure. Three other modifiers which differ from the adult terminology are discussed below.

### **Duration**

If the pattern is not continuous, then the typical duration of pattern is specified. Duration categories are provided, and the adult terminology also recommends recording the longest continuous duration.

- $\geq 1$  hour (“Very long”)
- 5-59 minutes (“Long”)
- 1-4.9minutes (“Intermediate duration”)
- 10-59 seconds (“Brief”)
- $< 10$  seconds (“Very brief”; distinct from BRDs for *lack of evolution*)

In one study, periodic discharge duration in the preterm infant was less than one minute and more than one minute for term infants.<sup>51</sup> Only 4/592 preterm and term infants had duration  $\geq 10$  minutes. Thus, while we define duration to be consistent with terminology used in the ICU for adult EEG, we recognize very few neonatal EEG patterns will fall into the “long” or “very long” categories.

### **Polarity**

In neonatal recordings, polarity should be determined in the traditional bipolar montage and should be specified for the predominant phase (phase with the greatest amplitude)

only for a *typical* discharge. Polarity applies only to PDs and the spike/sharp component of SW, not RDA. Polarity is categorized as positive, negative, or unclear.

### **Sharpness**

Sharpness applies only to PDs and the spike/sharp component of SW, but not to RDA. Sharpness should be specified for a typical discharge for both the predominant phase (phase with greatest amplitude) and the sharpest phase if different. Sharpness categories include:

- Spiky waveforms have a duration measured at the EEG baseline <100 msec.
- Sharp waveforms have a duration of 100-200 msec.
- Sharply contoured theta and delta waveforms have a sharp wave morphology (steep slope to one side of the wave and/or pointy at inflection point[s]) but are too long in duration to qualify as a sharp wave.
- Blunt waveforms have a smooth or sinusoidal morphology.

### **CONCLUSION**

This document is a collaborative effort to standardize the neonatal EEG terminology. We hope this common language fosters more effective multicenter collaboration to determine the significance of continuous EEG findings in critically ill neonates. Future work may build upon this framework to establish the utility of the proposed terms and definitions, both in the research and clinical realms. This terminology will be revised and updated based upon feedback and future research.

## REFERENCES

1. Murray DM, Boylan GB, Ali I, Ryan CA, Murphy BP, Connolly S. Defining the gap between electrographic seizure burden, clinical expression and staff recognition of neonatal seizures. *Arch Dis Child Fetal Neonatal Ed* 2008;93:F187-191.
2. Clancy RR, Legido A, Lewis D. Occult neonatal seizures. *Epilepsia* 1988;29:256-261.
3. Shellhaas RA, Chang T, Tsuchida T, et al. The American Clinical Neurophysiology Society's Guideline on Continuous Electroencephalography Monitoring in Neonates. *J Clin Neurophysiol* 2011.
4. Hirsch LJ, Claassen J, Mayer SA, Emerson RG. Stimulus-induced rhythmic, periodic, or ictal discharges (SIRPIDs): a common EEG phenomenon in the critically ill. *Epilepsia* 2004;45:109-123.
5. Vespa PM, Nenov V, Nuwer MR. Continuous EEG monitoring in the intensive care unit: early findings and clinical efficacy. *J Clin Neurophysiol* 1999;16:1-13.
6. Oddo M, Carrera E, Claassen J, Mayer SA, Hirsch LJ. Continuous electroencephalography in the medical intensive care unit. *Crit Care Med* 2009;37:2051-2056.
7. Orta DS, Chiappa KH, Quiroz AZ, Costello DJ, Cole AJ. Prognostic implications of periodic epileptiform discharges. *Arch Neurol* 2009;66:985-991.
8. Hirsch LJ, Brenner RP, Drislane FW, et al. The ACNS subcommittee on research terminology for continuous EEG monitoring: proposed standardized terminology for rhythmic and periodic EEG patterns encountered in critically ill patients. *J Clin Neurophysiol* 2005;22:128-135.
9. Engle WA. Age terminology during the perinatal period. *Pediatrics* 2004;114:1362-1364.
10. Brain Monitoring: Normal Neonatal EEG [computer program]. Ambler, PA: Moberg Multimedia, 2011.
11. Scher MS, Johnson MW, Holditch-Davis D. Cyclicity of neonatal sleep behaviors at 25 to 30 weeks' postconceptional age. *Pediatr Res* 2005;57:879-882.
12. Lamblin MD, Andre M, Challamel MJ, et al. [Electroencephalography of the premature and term newborn. Maturational aspects and glossary]. *Neurophysiol Clin* 1999;29:123-219.
13. Hahn JS, Monyer H, Tharp BR. Interburst interval measurements in the EEGs of premature infants with normal neurological outcome. *Electroencephalogr Clin Neurophysiol* 1989;73:410-418.
14. Scher MS. Electroencephalography of the newborn : normal and abnormal features. In: Niedermeyer E, Lopes da Silva FH, eds. *Electroencephalography*, 5th ed. Philadelphia: Lippincott Williams and Wilkins, 2005: 937-990.
15. Curzi-Dascalova L, Peirano P, Morel-Kahn F. Development of sleep states in normal premature and full-term newborns. *Dev Psychobiol* 1988;21:431-444.
16. Clancy RR, Dicker L, Cho S, et al. Agreement between long-term neonatal background classification by conventional and amplitude-integrated EEG. *J Clin Neurophysiol* 2011;28:1-9.

17. Mizrahi EM, Hrachovy RA, Kellaway P, Stockard-Pope JE. Atlas of neonatal electroencephalography, 3rd ed. Philadelphia: Lippincott Williams & Wilkins, 2004.
18. Clancy RA, Bergqvist AGC, Dlugos DJ. Neonatal Electroencephalography. In: Ebersole JS, Pedley TA, eds. Current practice of clinical electroencephalography, 3rd ed. Philadelphia: Lippincott Williams & Wilkins, 2003: 106-234.
19. Tharp BR, Cukier F, Monod N. The prognostic value of the electroencephalogram in premature infants. *Electroencephalogr Clin Neurophysiol* 1981;51:219-236.
20. Monod N, Pajot N, Guidasci S. The neonatal EEG: statistical studies and prognostic value in full-term and pre-term babies. *Electroencephalogr Clin Neurophysiol* 1972;32:529-544.
21. Holmes G, Rowe J, Hafford J, Schmidt R, Testa M, Zimmerman A. Prognostic value of the electroencephalogram in neonatal asphyxia. *Electroencephalogr Clin Neurophysiol* 1982;53:60-72.
22. Holmes GL, Lombroso CT. Prognostic value of background patterns in the neonatal EEG. *J Clin Neurophysiol* 1993;10:323-352.
23. Guideline 3: Minimum technical standards for EEG recording in suspected cerebral death. *J Clin Neurophysiol* 2006;23:97-104.
24. Ashwal S. Brain death in the newborn. *Clin Perinatol* 1989;16:501-518.
25. Ashwal S, Schneider S. Brain death in the newborn. *Pediatrics* 1989;84:429-437.
26. Volpe JJ. Brain death determination in the newborn. *Pediatrics* 1987;80:293-297.
27. Nakagawa TA, Ashwal S, Mathur M, Mysore M. Clinical Report--Guidelines for the Determination of Brain Death in Infants and Children: An Update of the 1987 Task Force Recommendations. *Pediatrics* 2011.
28. Biagioni E, Bartalena L, Biver P, Pieri R, Cioni G. Electroencephalographic dysmaturity in preterm infants: a prognostic tool in the early postnatal period. *Neuropediatrics* 1996;27:311-316.
29. Scher MS, Bova JM, Dokianakis SG, Steppe DA. Physiological significance of sharp wave transients on EEG recordings of healthy pre-term and full-term neonates. *Electroencephalogr Clin Neurophysiol* 1994;90:179-185.
30. Statz A, Dumermuth G, Mieth D, Duc G. Transient EEG patterns during sleep in healthy newborns. *Neuropediatrics* 1982;13:115-122.
31. Biagioni E, Boldrini A, Bottone U, Pieri R, Cioni G. Prognostic value of abnormal EEG transients in preterm and full-term neonates. *Electroencephalogr Clin Neurophysiol* 1996;99:1-9.
32. Clancy RR, Spitzer AR. Cerebral cortical function in infants at risk for sudden infant death syndrome. *Ann Neurol* 1985;18:41-47.
33. Rowe JC, Holmes GL, Hafford J, et al. Prognostic value of the electroencephalogram in term and preterm infants following neonatal seizures. *Electroencephalogr Clin Neurophysiol* 1985;60:183-196.
34. Karbowski K, Nencka A. Right mid-temporal sharp EEG transients in healthy newborns. *Electroencephalogr Clin Neurophysiol* 1980;48:461-469.
35. Clancy RR. Interictal sharp EEG transients in neonatal seizures. *J Child Neurol* 1989;4:30-38.
36. Clancy RR, Tharp BR. Positive rolandic sharp waves in the electroencephalograms of premature neonates with intraventricular hemorrhage. *Electroencephalogr Clin Neurophysiol* 1984;57:395-404.

37. Novotny EJ, Jr., Tharp BR, Coen RW, Bejar R, Enzmann D, Vaucher YE. Positive rolandic sharp waves in the EEG of the premature infant. *Neurology* 1987;37:1481-1486.
38. Scher MS, Bova JM, Dokianakis SG, Steppe DA. Positive temporal sharp waves on EEG recordings of healthy neonates: a benign pattern of dysmaturity in pre-term infants at post-conceptual term ages. *Electroencephalogr Clin Neurophysiol* 1994;90:173-178.
39. Chung HJ, Clancy RR. Significance of positive temporal sharp waves in the neonatal electroencephalogram. *Electroencephalogr Clin Neurophysiol* 1991;79:256-263.
40. Oliveira AJ, Nunes ML, Haertel LM, Reis FM, da Costa JC. Duration of rhythmic EEG patterns in neonates: new evidence for clinical and prognostic significance of brief rhythmic discharges. *Clin Neurophysiol* 2000;111:1646-1653.
41. Nagarajan L, Palumbo L, Ghosh S. Brief Electroencephalography Rhythmic Discharges (BERDs) in the Neonate With Seizures: Their Significance and Prognostic Implications. *J Child Neurol* 2011.
42. Shewmon DA. What is a neonatal seizure? Problems in definition and quantification for investigative and clinical purposes. *J Clin Neurophysiol* 1990;7:315-368.
43. D'Ambrosio R, Hakimian S, Stewart T, et al. Functional definition of seizure provides new insight into post-traumatic epileptogenesis. *Brain* 2009;132:2805-2821.
44. Mizrahi EM, Kellaway P. Characterization and classification of neonatal seizures. *Neurology* 1987;37:1837-1844.
45. Clancy RR, Legido A. The exact ictal and interictal duration of electroencephalographic neonatal seizures. *Epilepsia* 1987;28:537-541.
46. Scher MS, Hamid MY, Steppe DA, Beggary ME, Painter MJ. Ictal and interictal electrographic seizure durations in preterm and term neonates. *Epilepsia* 1993;34:284-288.
47. Pisani F, Copioli C, Di Gioia C, Turco E, Sisti L. Neonatal seizures: relation of ictal video-electroencephalography (EEG) findings with neurodevelopmental outcome. *J Child Neurol* 2008;23:394-398.
48. Shellhaas RA, Clancy RR. Characterization of neonatal seizures by conventional EEG and single-channel EEG. *Clin Neurophysiol* 2007;118:2156-2161.
49. McBride MC, Laroia N, Guillet R. Electrographic seizures in neonates correlate with poor neurodevelopmental outcome. *Neurology* 2000;55:506-513.
50. Scher MS, He BQ, Mazumdar S, Painter MJ, Alvin J, Redmond CK. A Reliability Study of a Neonatal Seizure Scoring System. *J Epilepsy* 1994;7:273-278.
51. Scher MS, Beggary M. Clinical significance of focal periodic discharges in neonates. *J Child Neurol* 1989;4:175-185.
52. Sainio K, Granstrom ML, Pettay O, Donner M. EEG in neonatal herpes simplex encephalitis. *EEG Clin Neurophysiol* 1983; 56:556-561.
53. Mikati MA, Feraru E, Krishnamoorthy K, Lombroso CT. Neonatal herpes simplex meningoencephalitis: EEG investigations and clinical correlates. *Neurology* 1990; 40:1433-1437.

Figure legends

Box 1. DETAILS TO INCLUDE IN DAILY EEG REPORT

Box 2. BEHAVIORAL STATE

Figure 1. Examples of EEG background classification by voltage.

Figure 2. Examples illustrating the contrasts between *tracé discontinu*, *tracé alternant*, excessive discontinuity, and burst suppression. EEG tracings courtesy of Clancy, RR and Wusthoff, CJ. Brain monitoring: Normal Neonatal EEG. Moberg Multimedia. Ambler, PA. 2011

Figure 2a. In *tracé discontinu*, the bursts are separated by very low voltage, suppressed interburst intervals. There are no artifacts from EMG activity or movement and the respiratory pattern is quite regular.

Figure 2b. In this example of *tracé alternant*, however, there is an alternating pattern of high and low voltages, but no periods that are consistently suppressed. There are no artifacts from EMG activity or movement and the respiratory pattern is quite regular.

Figure 2c. This excessively discontinuous record from a term infant with an acute encephalopathy shows prolonged interburst intervals, though with some normal features present during bursts, such as the conspicuous *encoche frontale* seen near its onset (arrow).

Figure 2d. Burst suppression, in contrast, contains prolonged, extremely suppressed interburst intervals and bursts comprised exclusively of abnormal electrical activity.

Box 3. EEG BACKGROUND

Table 1. Normal interburst interval (IBI) duration and amplitude. Values for IBI duration and amplitude vary with postmenstrual age.

Box 4. NORMAL GRAPHOELEMENTS

Box 5. EEG TRANSIENT PATTERNS

Figure 3. Examples illustrating the contrasts between *encoches frontales*, physiologic sharp waves, and pathologic sharp waves.

Figure 3a. *Encoches frontales* are present and synchronous in both frontal regions.

Figure 3b. A physiologic sharp wave is seen in the 13th second on this page, in the right mid-temporal region (T4).

Figure 3c. Pathologic periodic sharp waves are seen in the left anterior quadrant. These occur frequently, and repetitively in the same location. The first three are highlighted with arrows.

**Box 6. SEIZURES AND STATUS EPILEPTICUS**

**Box 7. RHYTHMIC AND PERIODIC PATTERNS OF UNCERTAIN SIGNIFICANCE**



## Figures and Tables

### Box 1

#### DETAILS TO INCLUDE IN DAILY EEG REPORT

- Patient Postmenstrual Age
- Neuroactive medications in use during recording
- Use of hypothermia during recording
- Clinical changes that may impact cerebral function
- Documentation of duration of recording (in hours) uninterpretable due to technical problems
- Characterization of background features during first hour of monitoring
- Characterization of one hour of background within each subsequent 24 hour epoch
- Characterization of additional epochs when background changes
- Seizure onset, burden, and resolution
- Presence, onset, and resolution of status epilepticus

## Box 2

### BEHAVIORAL STATE

- Awake
- Asleep
  - Active Sleep
  - Quiet Sleep
- Transitional Sleep
- Indeterminate Sleep
- Sleep-wake Cycling

Figure 1.  
Figure 1. Examples of EEG background classification by voltage.

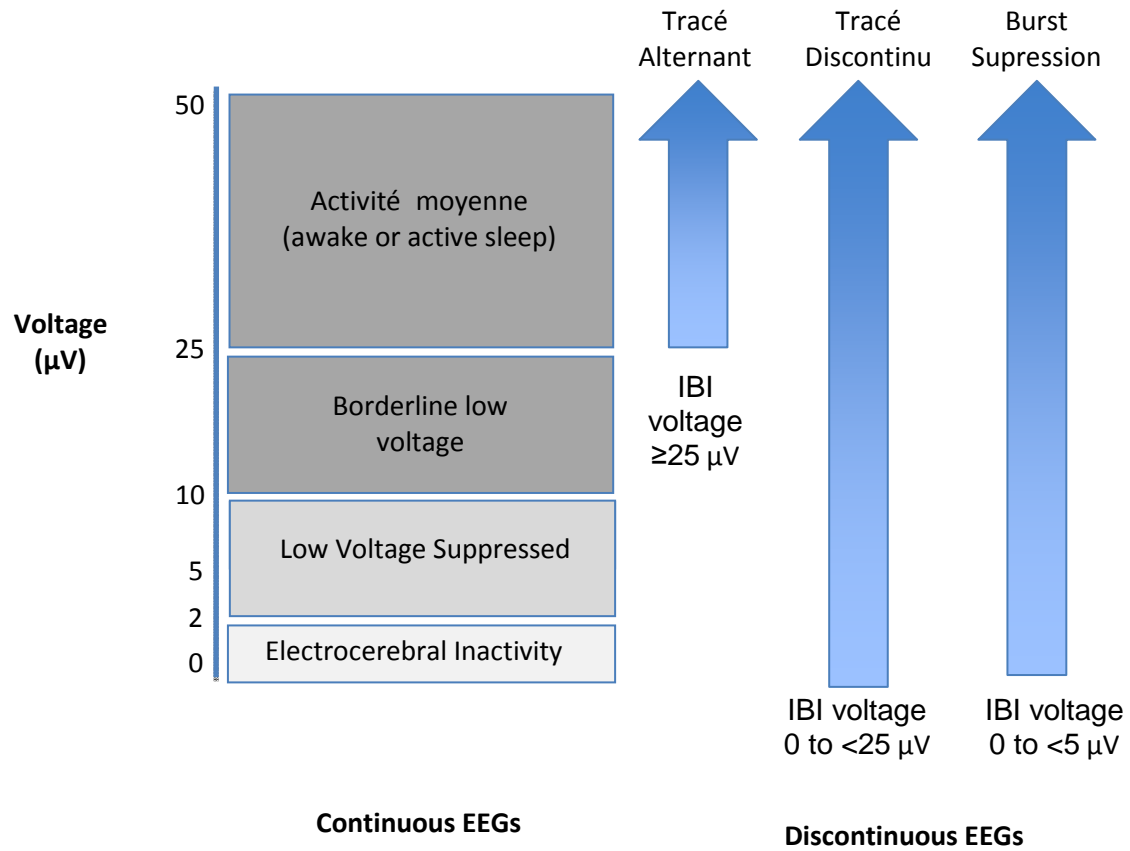


Figure 2. Examples illustrating the contrasts between tracé discontinu, tracé alternant, excessive discontinuity, and burst suppression. EEG tracings courtesy of Clancy, RR and Wusthoff, CJ. Brain monitoring: Normal Neonatal EEG. Moberg Multimedia. Ambler, PA. 2011.

Figure 2a. In tracé discontinu, the bursts are separated by very low voltage, suppressed interburst intervals. There are no artifacts from EMG activity or movement and the respiratory pattern is quite regular.

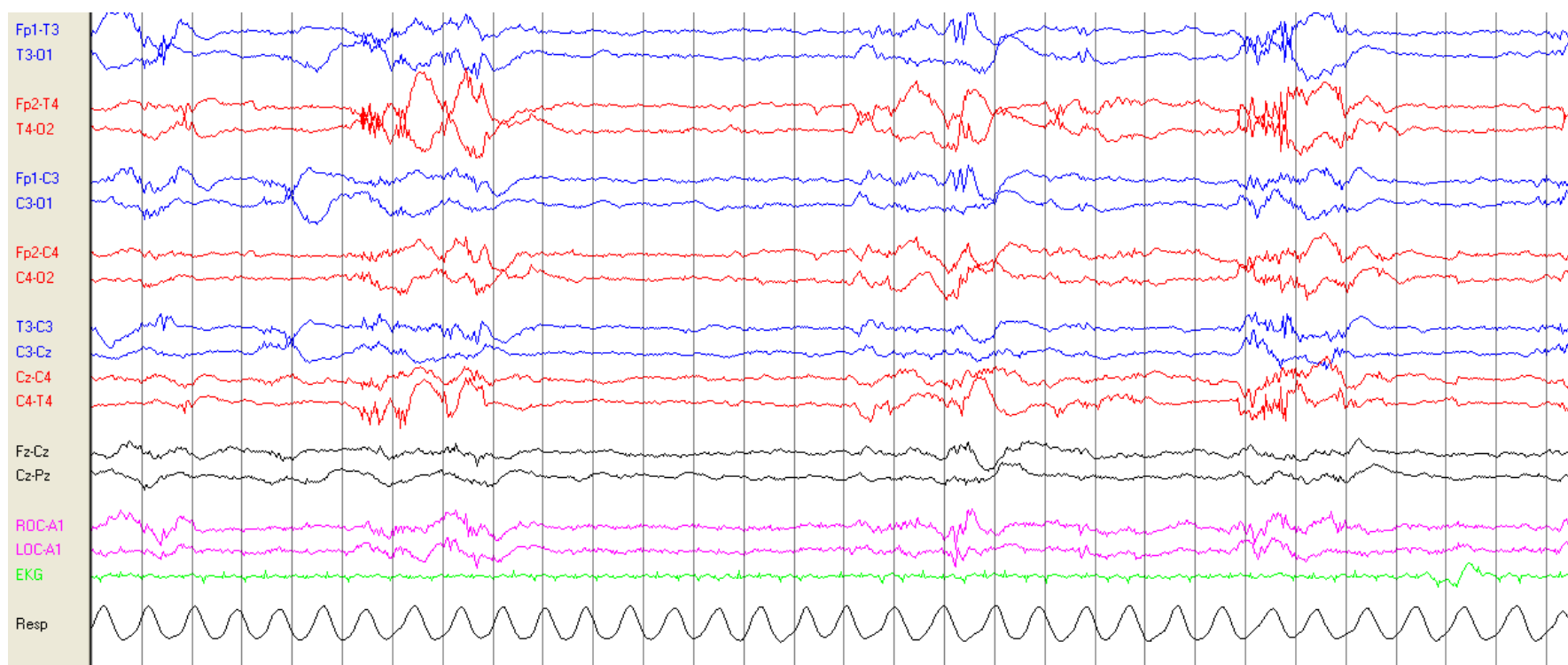


Figure 2b. In this example of tracé alternant, however, there is an alternating pattern of high and low voltages, but no periods that are consistently suppressed. There are no artifacts from EMG activity or movement and the respiratory pattern is quite regular.

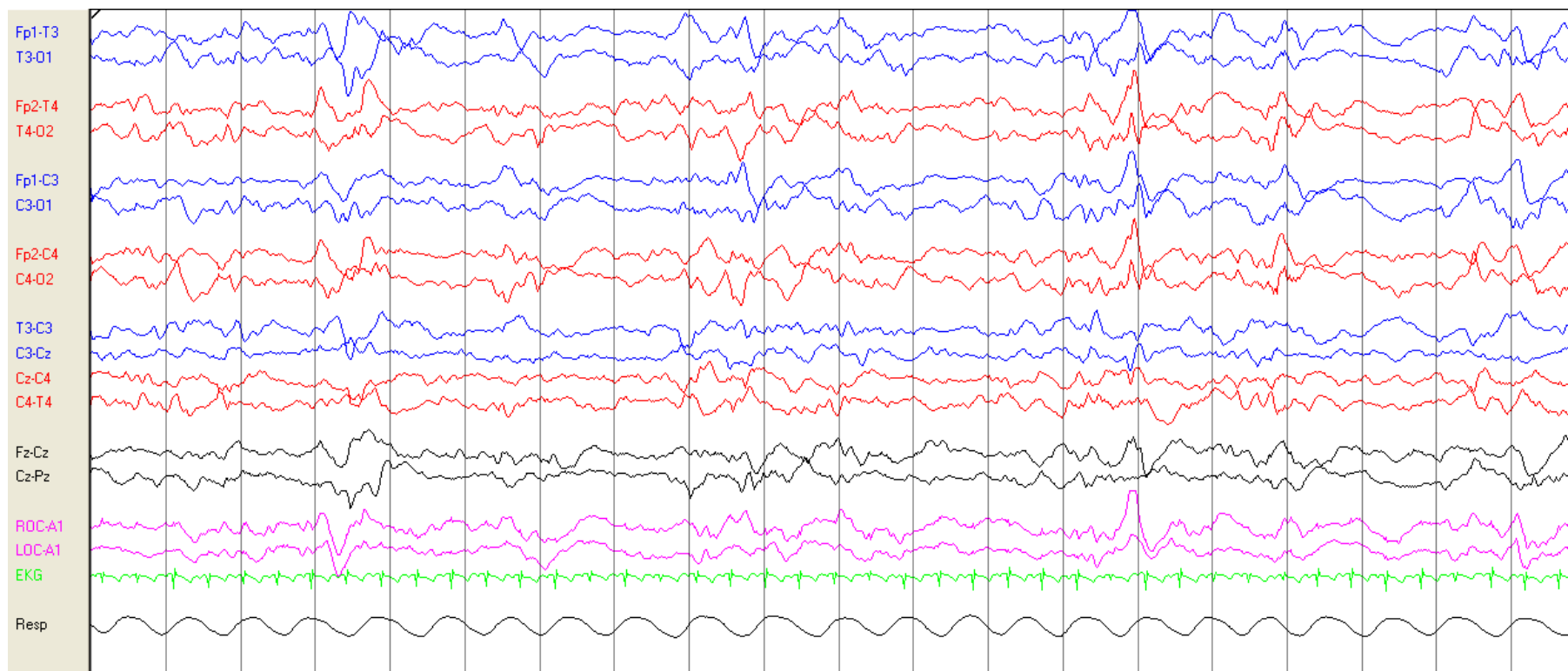


Figure 2c. This excessively discontinuous record from a term infant with an acute encephalopathy shows prolonged interburst intervals, though with some normal features present during bursts, such as the conspicuous encoche frontale seen near its onset (arrow).

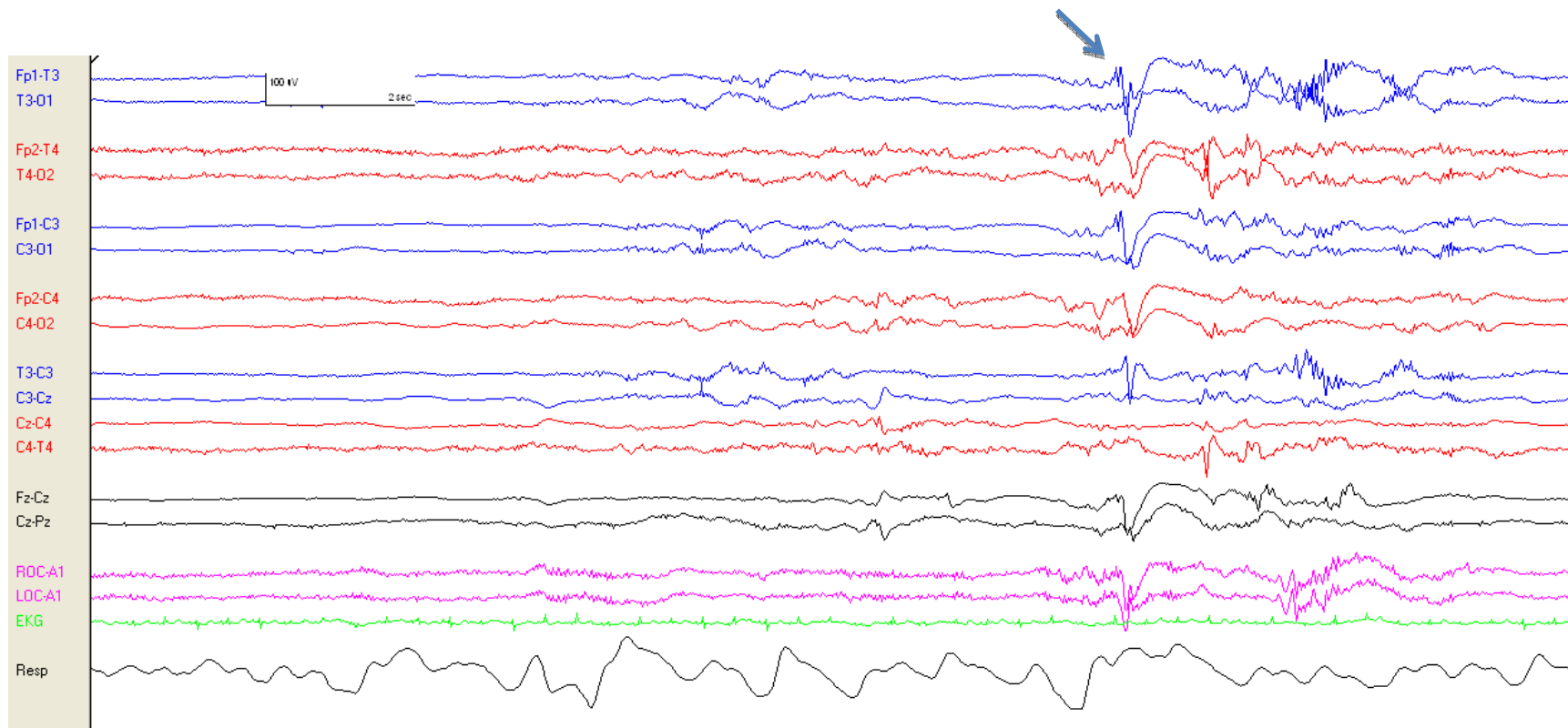
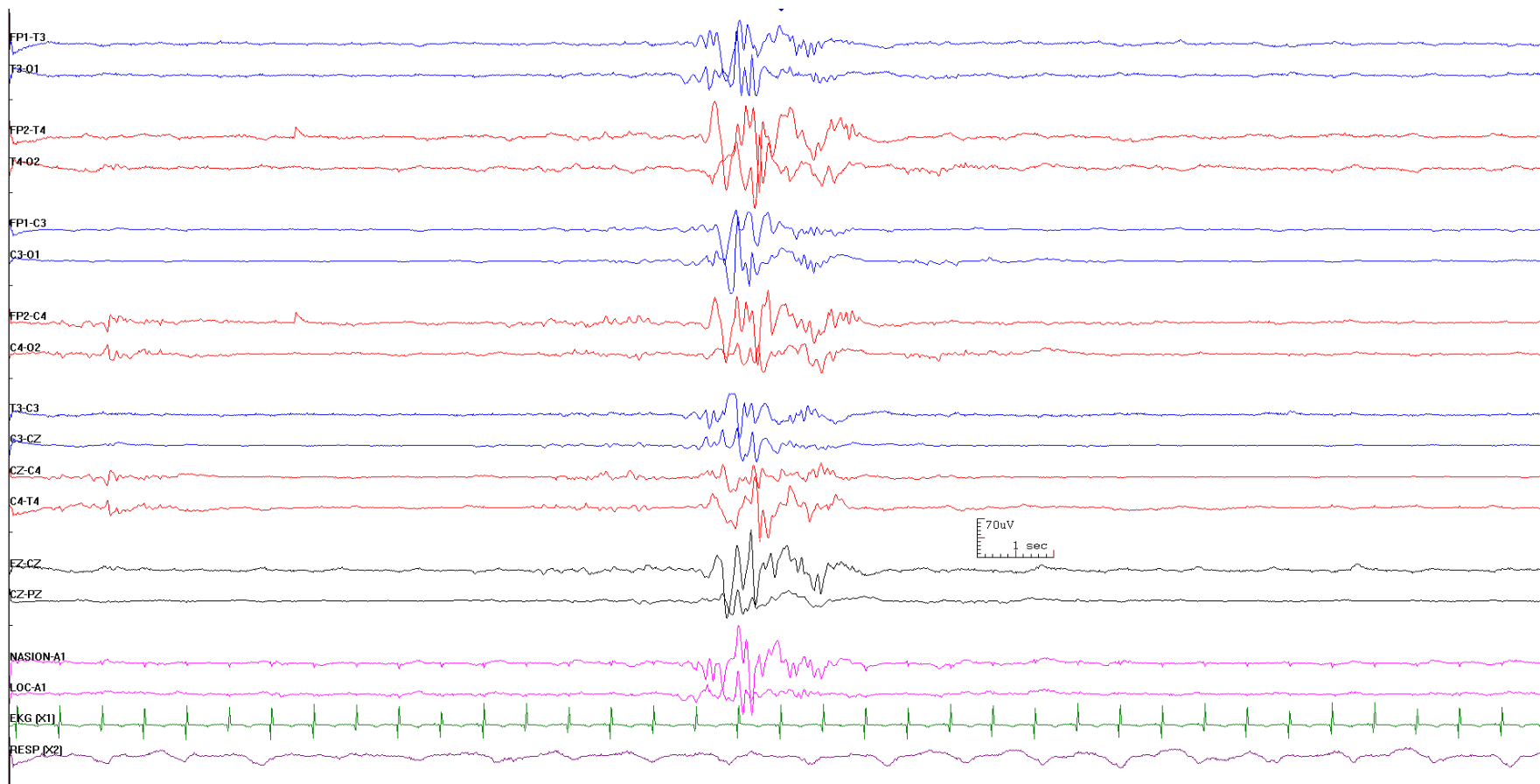


Figure 2d. Burst suppression, in contrast, contains prolonged, extremely suppressed interburst intervals and bursts comprised exclusively of abnormal electrical activity.



## Box 3

### EEG BACKGROUND

- Continuity
  - Normal Continuity
  - Normal Discontinuity
  - Excessive Discontinuity
  - Burst Suppression
- Symmetry
- Synchrony
- Voltage
  - Normal voltage
  - Borderline low voltage
  - Abnormally low voltage
    - Low Voltage Suppressed
    - Electroencephalographic inactivity
- Variability
- Reactivity
- Dysmaturity



Table 1. Normal interburst interval (IBI) duration and amplitude. Values for IBI duration and amplitude vary with postmenstrual age.

Postmenstrual Age	Maximum interburst interval	Voltage of interburst
< 30 weeks	35 seconds	<25 $\mu$ V
30-33 weeks	20 seconds	<25 $\mu$ V
34-36 weeks	10 seconds	~25 $\mu$ V
37-40 weeks	6 seconds	>25 $\mu$ V

## Box 4

### NORMAL GRAPHOELEMENTS

- Monorhythmic Delta Activity
- Delta Brushes
- Rhythmic Temporal Theta
- Anterior Dysrhythmia
- Encoches Frontales

## Box 5

### EEG TRANSIENT PATTERNS

- Negative Sharp Wave Transients
  - Physiologic Negative Sharp Waves
  - Abnormal Negative Sharp Waves
- Positive Sharp Transients
- Brief Rhythmic Discharges (BRD)

Figure 3. Examples illustrating the contrasts between encoches frontales, physiologic sharp waves, and pathologic sharp waves.

Figure 3a. Encoches frontales are present and synchronous in both frontal regions.

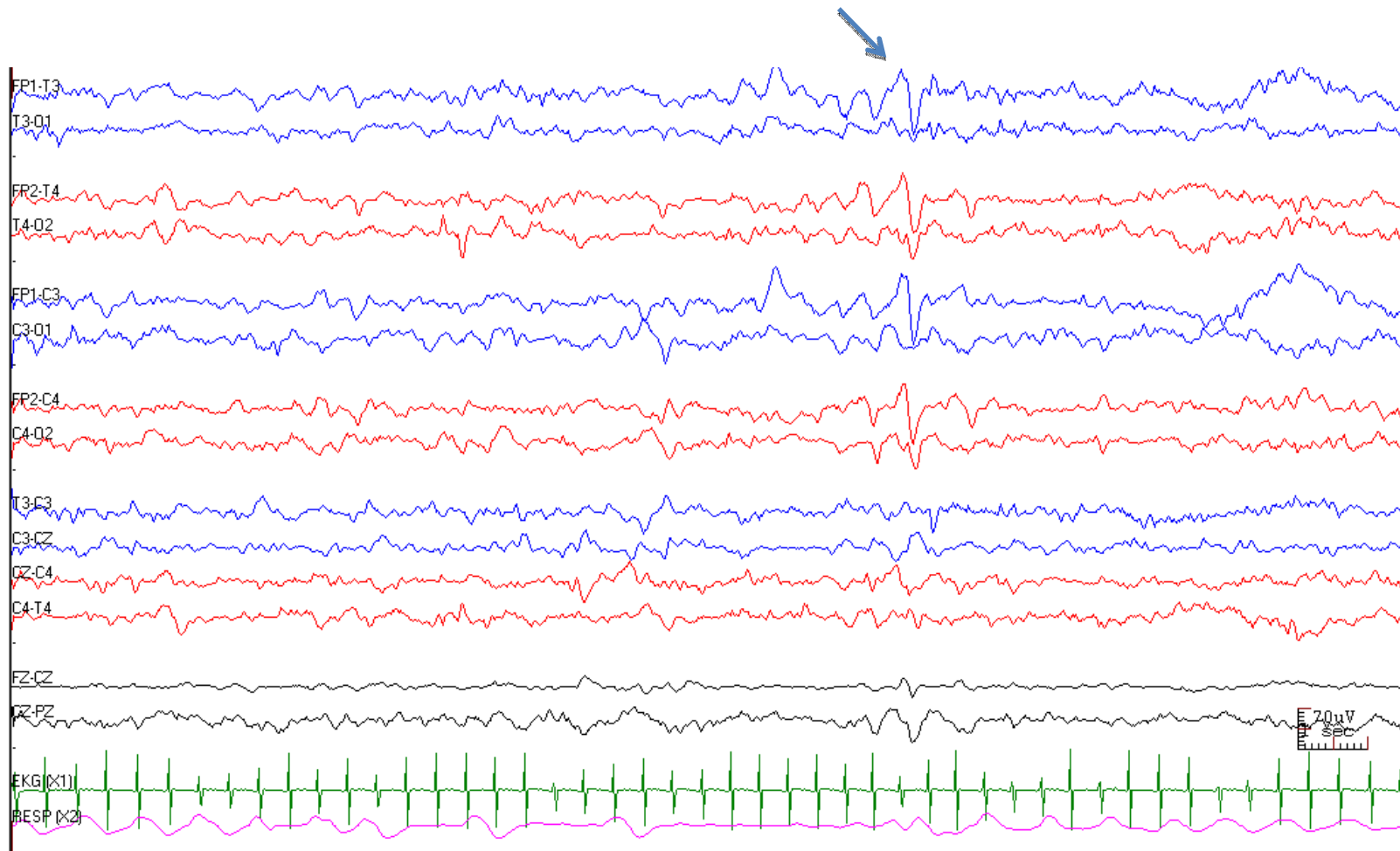


Figure 3b. A physiologic sharp wave is seen in the 13th second on this page, in the right mid-temporal region (T4).

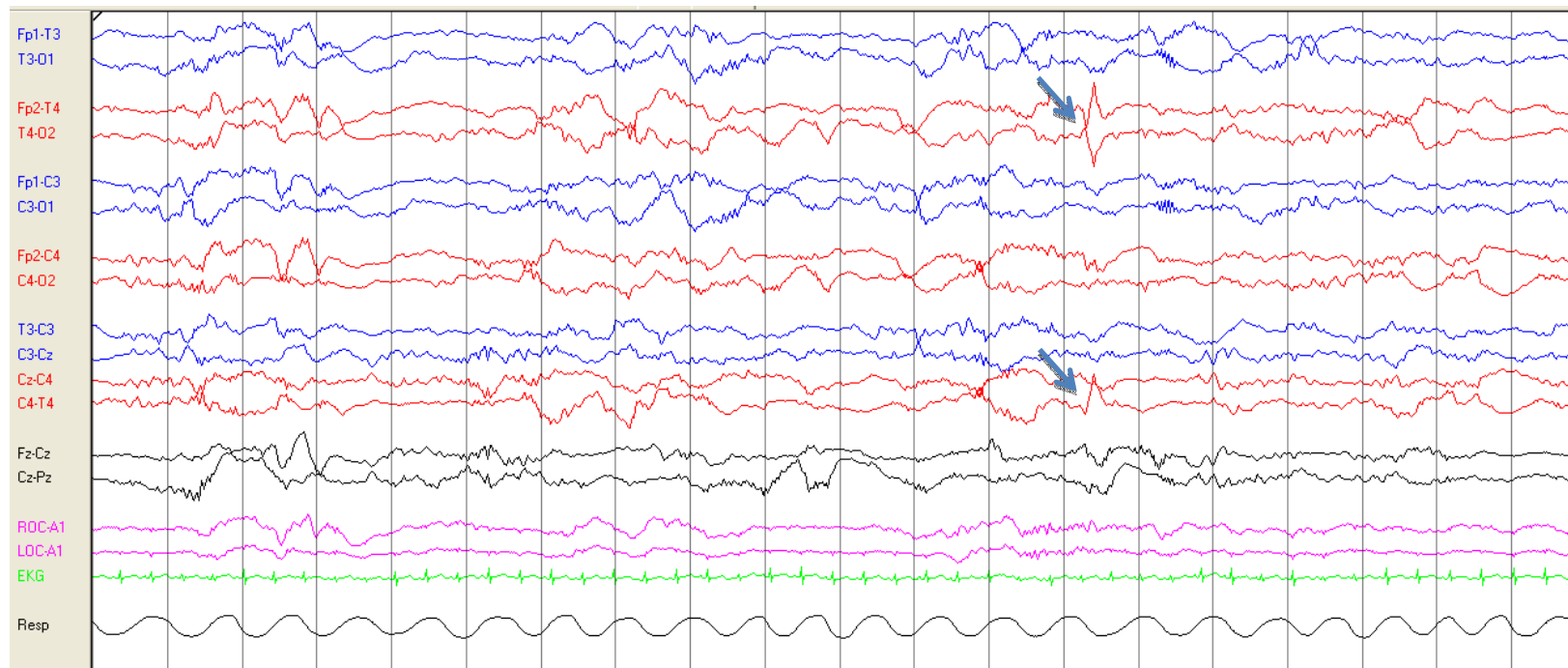
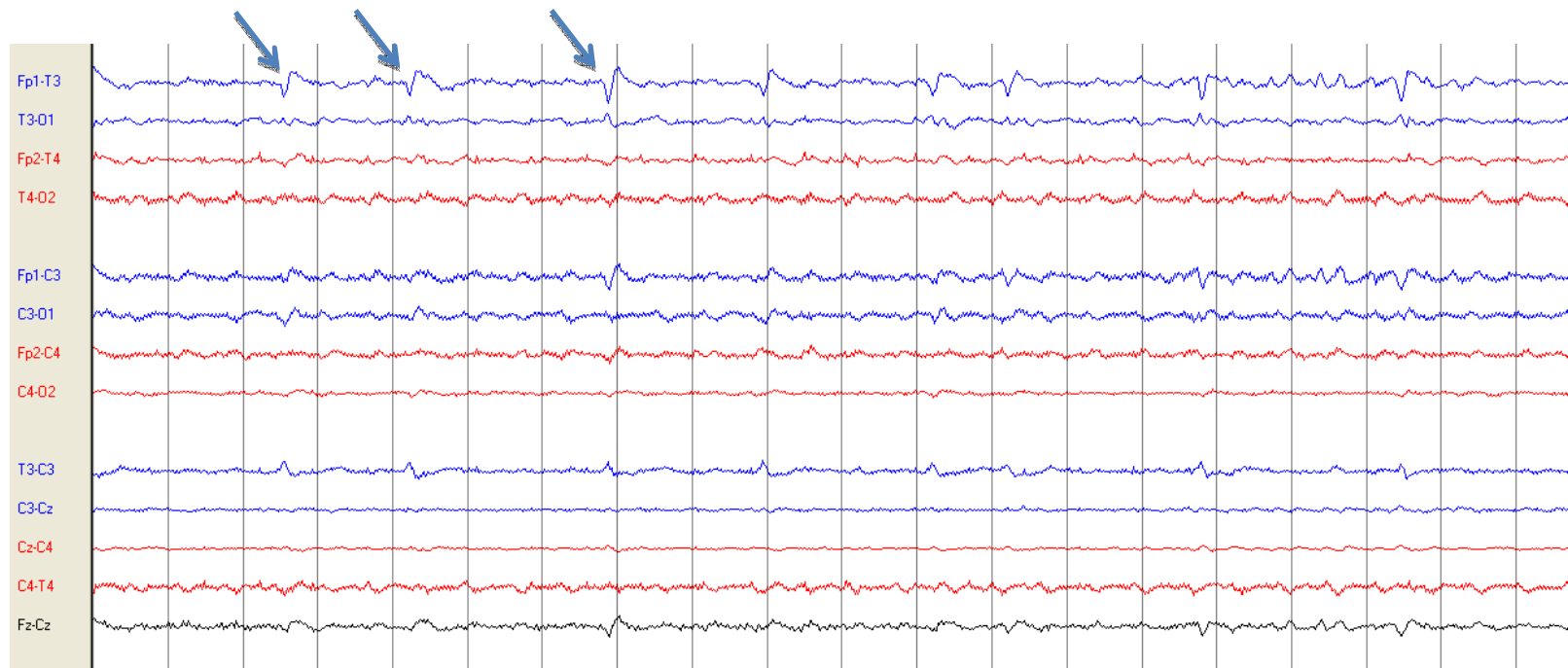


Figure 3c. Pathologic periodic sharp waves are seen in the left anterior quadrant. These occur frequently, and repetitively in the same location. The first three are highlighted with arrows.



## Box 6

### SEIZURES AND STATUS EPILEPTICUS

- Seizures
  - Duration  $\geq$  10 seconds
  - Location
    - Diffuse (D)
    - Lateralized (L)
      - Hemispheric- left (LH), right (RH)
    - Focal
      - Frontal (F)
      - Central (C)
      - Temporal (T)
      - Occipital (O)
      - Vertex (Z)
      - Quadrant- anterior (Ant), posterior (Post)
    - Bilateral Independent (BI)
    - Multifocal (Mf)
    - Migrating (Mig)
  - Seizure Burden
    - Number of seizures per hour or
    - Summed duration of seizures divided by duration of epoch
- Status Epilepticus- summed duration of seizures totals  $\geq$  50% of a 1hr epoch

## Box 7

### RHYTHMIC AND PERIODIC PATTERNS OF UNCERTAIN SIGNIFICANCE

- Pattern
  - Periodic discharges (PD )
  - Rhythmic delta activity (RDA)
- Duration
- Location
  - Lateralized (L)
    - Focal
    - Hemispheric- left (LH), right (RH)
    - Bilateral asymmetric
  - Diffuse (D)
  - Bilateral Independent (BI)
  - Multifocal (Mf)
- Modifiers (subset of ACNS Standardized Critical Care EEG Terminology 2012)
  - Duration
  - Polarity
  - Sharpness